

DOI: 10.21767/2471-8300.100044

## Handling a Sticky Ticky Issue

Sucheta Parija<sup>1</sup> and Bijnya Birajita Panda<sup>2\*</sup>

<sup>1</sup>Department of Ophthalmology, All India Institute of Medical Sciences Bhubaneswar, Odisha, India

<sup>2</sup>Department of Ophthalmology, S.C.B Medical College and Hospital, Odisha, India

\*Corresponding author: Bijnya Birajita Panda, S.C.B Medical College and Hospital, Odisha, India, Tel: 07788969639; E-mail: bigyan\_panda@yahoo.co.in

Received date: November 14, 2018; Accepted date: November 20, 2018; Published date: November 28, 2018

Citation: Parija S, Panda BB (2018) Handling a Sticky Ticky Issue. J Eye Cataract Surg 4: 1. doi: 10.21767/2471-8300.100044

Copyright: ©2018 Parija S, et al. This is an open-access article distributed under the terms of the Creative Commons Attribution License, which permits unrestricted use, distribution, and reproduction in any medium, provided the original author and source are credited.

### Abstract

Tick infestation of the lower eye lid is quite a rare condition. We describe the case of a 50-year-old woman who presented with pain and itching of her right lower eyelid. Slit lamp examination revealed a tick strongly attached to the eyelid margin. The tick was successfully removed using fine forceps, and within one week, the patient fully improved without any complications. Ticks are a public health hazard as they are known vectors of numerous infectious agents responsible for Lyme disease. Ticks may also provoke cutaneous anaphylactic reactions, and rarely, tick paralysis. Therefore, there is a need to make people aware of the presence of this parasite in our environment even in urban scenarios. Early and complete extraction of the parasite can prevent severe anaphylactic reaction and transmission of zoonoses.

**Keywords:** Tick; Lyme disease; Zoonoses

### Introduction

Tick bite near eyelid is uncommonly seen in ophthalmic practice, mostly in spring and summer season in rural societies, more likely in people having pets, cattle or horses [1]. Ticks are obligatory bloodsucking Ectoparasites that infest mammals, birds, reptiles and amphibians. There are two classes of ticks which are mainly responsible for manifestation of diseases in humans: hard ticks (family Ixodidae) and soft ticks (family Argasidae). Soft ticks take smaller, take quicker blood meals at shorter intervals, and can transmit pathogens quickly within minutes than hard ticks which can take hours to days. However, hard ticks are more common, harder to remove and more likely to transmit disease.

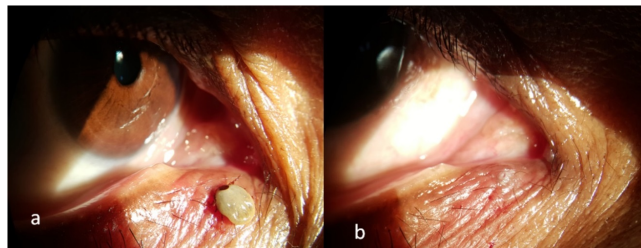
Only 10% of the hard and soft tick species have been reported to be involved in disease transmission to domestic animals and humans. *Hyalomma anatolicum* and *Haemaphysalis spinigera* are the two important species of ticks present in India, which are responsible for causing the fatal tick-borne viral diseases of Crimean-Congo hemorrhagic fever (CCHF) and Kyasanur forest disease (KFD), respectively [2,3]. There are several other

rickettsial infections like Rickettsioses and Boutonneuse fever (caused by *Rickettsia conorii* found in Europe), transmitted by *Rhipicephalus sanguineus* and other tick species. Man is an occasional host. They have three life stages: larvae, nymph, and adult stages. The development of ticks depends on a series of moults, especially in the nymph developmental stage. Each blood meal helps them move onto the next stage of their life cycle. We report a 50-year-old woman presenting to the emergency services with severe pain and itching around the medial canthus of right eye (**Figure 1a**). She had no prior history of epiphora, trauma or swelling. On slit-lamp examination, an insect with body parts was seen strongly adhered to the soft tissue of medial canthus. The skin around the tick bite was erythematous and swollen. The tick was removed with the help of tissue forceps with extreme precautions to ensure complete removal (**Figure 1b**). She was prescribed with topical antibiotic ointment, systemic anti-inflammatory agents, analgesics and oral antihistamines. She recovered completely within a week and without any complications. The animal was sent to laboratory and was found to be of *Hyalomma* species on identification. The patient was properly explained about possible sign and symptoms of tick borne diseases was informed about prophylaxis measures like wearing glasses while being close with cattle's. Patient was referred to the infectious diseases department for further evaluation.

### Discussion

Ticks are ranked second only to mosquitoes as vectors. They can transmit numerous human pathogens like viruses, bacteria, rickettsiae, spirochetes. Major tick-borne diseases prevalent in India include Indian tick typhus, Crimean-Congo hemorrhagic fever, Theileriosis, Babesiosis, Bovine anaplasmosis, Lyme disease etc. [4]. Extreme precautions have to be taken while removal of the tick such as extracting the tick completely taking care that no remnant remains attached to the skin since it may cause severe inflammatory or infectious reaction or chances of transmission of zoonoses. Few authors have used gasoline or lighter fuel while extraction of the tick [5,6]. In our case, we fortunately removed the tick completely with the help of a tissue forceps without using any chemical. The importance of highlighting this case report is the need to make aware of the

presence of this parasite in our environment even in urban scenario and the need for early and complete extraction of the parasite to prevent severe anaphylactic reaction and transmission of zoonoses.



**Figure 1:** (a) A tick strongly adhered to the soft tissue of medial canthus of right eye. (b) After removal with forceps, the bite mark seen as an avascular area over the skin.

## Conclusion

Tick manifestation of ocular tissues is a rare entity. The tick must be completely removed from the eyelid as early as possible, because the chances of disease transmission increase with duration of infestation. Complete removal of the tick under slit lamp supervision is safe and effective treatment for ticks located on the eyelids. Patient must be informed about sign and symptoms of tick related disease and prophylactic measures to

be undertaken while managing cattles. The importance of highlighting this case report is the need to make aware of the presence of this parasite in our environment even in urban scenarios and the need for early and complete extraction of the parasite to prevent severe anaphylactic reaction and transmission of zoonoses.

## References

1. Samaha A, Green WR, Traboulsi EI, Ma'luf R (1998) Tick infestation of the eyelid. *Am J Ophthalmol* 125: 263-264.
2. Yadav PD, Gurav YK, Mistry M, Shete AM, Sarkale P, et al. (2013) Emergence of Crimean-Congo hemorrhagic fever in Amreli District of Gujarat State, India, June to July 2013. *Int. J Infect Dis* 18: 97-100.
3. Mourya DT, Yadav PD, Sandhya VK, Reddy S (2013) Spread of Kyasanur Forest disease, Bandipur Tiger Reserve, India, 2012–2013. *Emerg Infect Dis* 19:1540-1541.
4. Ghosh S, Nagar G (2014) Problem of ticks and tick-borne diseases in India with special emphasis on progress in tick control research: a review. *J Vector Borne Dis* 51: 259-270.
5. Keklikçi U, Unlü K, Cakmak A, Akdeniz S, Akpolat N, et al. (2009) Tick infestation of the eyelid: a case report in a child. *Turk J Pediatr* 51:172-173.
6. Bowes OM, Legg G, Haines R, Vardy SJ (2015) Tick infestation of the upper eyelid. *Can J Ophthalmol* 50: 39-40.